

NIH RELAIS Document Delivery

NIH-10114484

NIH -- W1 VE9332JF

ANDREW SILVERSTONE
MSC 1907
NCI, Building 10, 12C116
Bethesda, MD 20892

ATTN:	SUBMITTED:	2002-01-18 12:00:02
PHONE: 301-435 8061	PRINTED:	2002-01-23 14:47:28
FAX: -	REQUEST NO.:	NIH-10114484
E-MAIL:	SENT VIA:	LOAN DOC 5593729

NIH	Fiche to Paper	Journal
TITLE:	VETERINARY RADIOLOGY _ULTRASOUND : THE OFFICIAL JOURNAL OF THE AMERICAN COLLEGE OF VETERINARY RADIOLOGY AND THE INTERNATIONAL VETERINARY RADIOLOGY ASSOCIATION	
PUBLISHER/PLACE:	American College Of Veterinary Radiology Raleigh Nc	
VOLUME/ISSUE/PAGES:	1999 Sep-Oct;40(5):477-9	477-9
DATE:	1999	
AUTHOR OF ARTICLE:	Silverstone AM; Adams WM	
TITLE OF ARTICLE:	Radiographic diagnosis--gastrobronchial fistula in	
ISSN:	1058-8183	
OTHER NOS/LETTERS:	Library does NOT report holding title 9209635 10528841	
SOURCE:	PubMed	
CALL NUMBER:	W1 VE9332JF	
REQUESTER INFO:	ANDREWSDVM	
DELIVERY:	E-mail: silversa@mail.nih.gov	
REPLY:	Mail:	

NOTICE: THIS MATERIAL MAY BE PROTECTED BY COPYRIGHT LAW (TITLE 17, U.S. CODE)

-----National-Institutes-of-Health,-Bethesda,-MD-----

RADIOGRAPHIC DIAGNOSIS OF GASTROBRONCHIAL FISTULA IN A DOG

ANDREW M. SILVERSTONE, BA, WILLIAM M. ADAMS, DVM

Veterinary Radiology & Ultrasound, 40:477-479, 1999

Signalment

A five-year-old, 21 kilogram, intact female collie.

History

The patient was referred to the Veterinary Medical Teaching Hospital for evaluation of suspected laryngeal paralysis because of gagging and coughing of 1-month duration. The dog had been treated with tetracycline followed by penicillin and gentamycin together, but signs persisted.

Physical Examination

The dog was febrile (39.9°C) and had a productive continuous hacking cough with expectoration of brownish phlegm. On auscultation there were increased vesicular sounds and crackling in the cranioventral lung field. Suppurative exudate with a mixed bacterial population consistent with aspiration pneumonia was identified on a transtracheal wash. Because of the gagging, suspicion of aspiration, and poor response to antibiotic therapy, a swallowing disorder and esophageal dysfunction were differential diagnoses.

Radiographic Findings

On thoracic radiographs a mixed alveolar/interstitial infiltrate was seen in the ventral half of the lung field (Fig. 1). Alveolar infiltrates were evident in the ventral portions of all right lung lobes (Fig. 1 and 2). Bronchi in the affected lobes were dilated and irregular, and cranial displacement of the pylorus and right cardiac displacement was observed (Fig. 3). An esophagram was done using 40 cc of 100% barium paste* per os. Swallowing observed under fluoroscopy was within normal limits. No esophageal abnormalities were seen during fluoroscopy. During evaluation of gastric contraction, contrast medium appeared in the right caudal lung lobe. On subsequent radiographs, a fistula from the cranial margin of the displaced pylorus to the right caudal

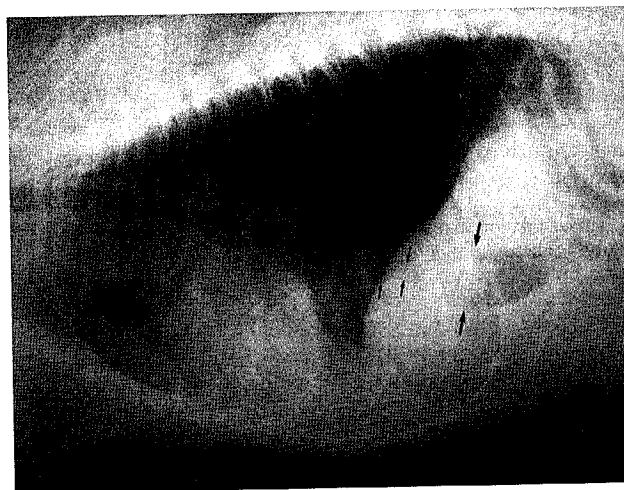

FIG. 1. Left lateral thorax. The ventral aspect of the lung has mixed interstitial and alveolar infiltrates with dilated irregular bronchi to the right cranial and middle lung lobes. Note cranial location of the pylorus (large arrows). The liver margin is caudal to the pylorus (open arrow). Note location of small arrows (see Figure 2).

lobe bronchus was seen (Fig. 4). The fistula was 2 mm wide and 1 cm long (Figs. 4, 5). Saccular dilation of a terminal bronchus of the right caudal lung lobe is identified. Bronchograms occurred in all the right lung lobes ventrally, outlining irregular bronchial walls.

Radiographic Diagnosis

Right, cranial, middle, and caudal lobar bronchopneumonia and saccular bronchiectasis. Pneumonia distribution is consistent with aspiration. Gastrobronchial fistula between the pylorus and the right caudal lung lobe.

Treatment and Follow-Up

An 18 inch incision was made on the ventral midline from the manubrium to the mid-abdomen. The thoracic cavity was opened by sternal splitting. The stomach (proximal to the pylorus) and liver were adhered to the diaphragm. There were diaphragmatic adhesions of the consolidated portion of the caudal right lung lobe opposite pyloric adhesions to the abdominal side of the diaphragm. The entire right lung, part of the pyloric portion of the stomach, and a portion of the right side of the diaphragm were excised. No evidence of foreign body was found.

Histopathologically (only lung was submitted), extensive

From the Department of Surgical Sciences, School of Veterinary Medicine, University of Wisconsin, 2015 Linden Drive West, (Madison, WI 53706)

Address correspondence and reprint requests to Mr. Andrew M. Silverstone at the address below.

Mr. Silverstone's current address is the Atlantic Veterinary College, University of Prince Edward Island, 550 University Avenue, Charlottetown, Prince Edward Island, C1A 4P3 Canada.

Received August 19, 1998; accepted for publication December 7, 1998.

*E-Z-Paste, E-Z-EM, Westbury, NY 11590.

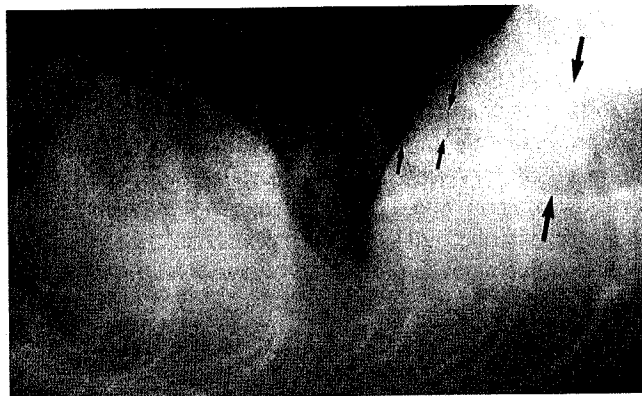


FIG. 2. Close-up, left lateral caudal thorax. Note the gas opacity partially superimposed on the diaphragm (short arrows) suggesting a caudal lung abscess. Again, the large arrows indicate the mal-positioned pylorus. There is marked dilation and irregularity of the bronchus in the consolidated portion of the right middle lung lobe.

bronchiolar dilation was found in the right lung. Diffuse squamous metaplasia of airway epithelium with multifocal ulceration was present in the larger airways. Bronchial ducts were dilated and edematous. Bronchial cartilage was atrophic. Peripheral lung tissues were filled with mucoid and suppurative material. The final diagnosis was chronic, irritative bronchiectasis with bronchopneumonia, secondary to gastrobronchial fistula.

Enrofloxacin† and Ciprofloxacin‡ sensitive strains of *Enterobacter sakazakii* and *E. coli* were isolated from the resected lung. Enrofloxacin† (68 mg/Kg BID) was given for 15 days. Following six days of hospitalization and treatment for post-surgical pneumothorax and hydrothorax the dog was released. The owner reported the dog made a complete recovery, lived six more years, and died of liver disease.

†Baytril®, Bayer Corporation, Shawnee Mission, KS 66201.

‡Ciprofloxacin®, Bayer Corporation, Shawnee Mission, KS 66201.

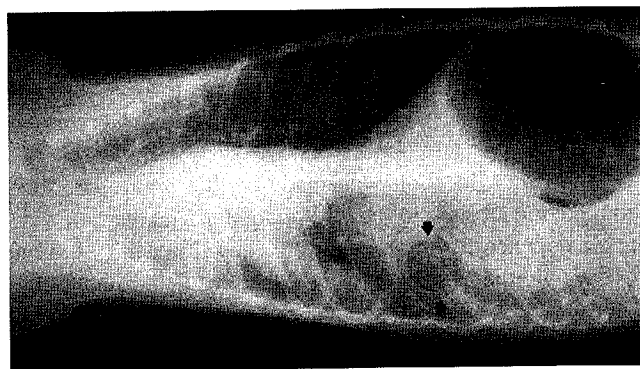


FIG. 3. Dorso-ventral thorax. The left lung lobes are hyperinflated relative to the right lung lobes, causing a mediastinal shift to the right. Consolidated right lung lobes obscure the heart. Note location of the pylorus (arrows) cranial to the gastric fundus and consistent with cranial pylorus displacement noted on the left lateral view (Figure 1).

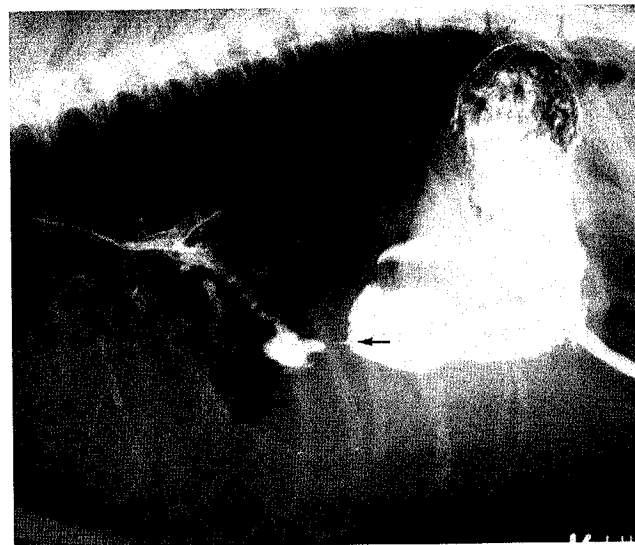

FIG. 4. Right lateral view centered on the diaphragm following oral administration of barium paste. There is a communication between the pylorus and the lung via a thin fistula (arrow). The gas opacity outlined in Figure 2 is now barium filled. Several bronchi are outlined with barium.

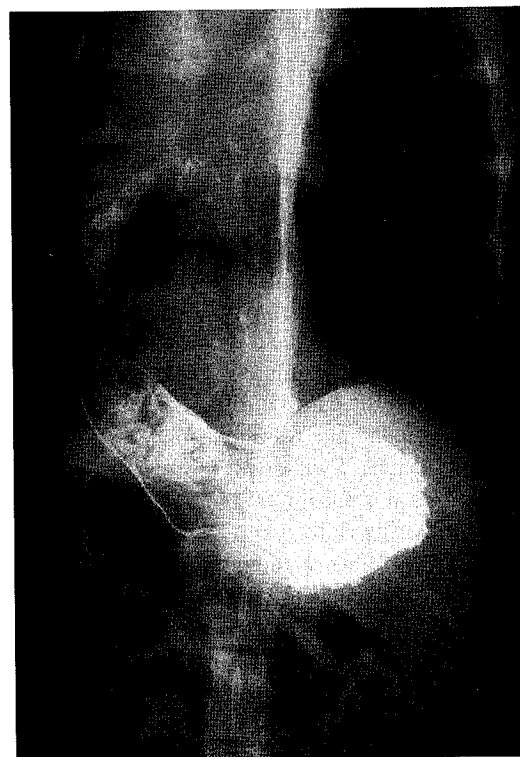


FIG. 5. Dorso-ventral view following oral administration of barium paste. Communication between the pylorus and the right caudal lung lobe is verified. Barium extends to the tracheal bifurcation. The heart and tracheal bifurcation are deviated to the right, indicating loss of right lung volume and possible adhesions. No communication is seen between the esophagus and the respiratory tract.

Discussion

Clinical signs in the dog presented here were consistent with recurrent aspiration. The salient signs on survey thoracic radiography were pyloric displacement with a normal sized liver and the subtle gas opacity superimposed on the diaphragm which suggested abscess or saccular bronchial dilation. The esophagram/gastrogram provided definitive evidence of a gastrobronchial fistula.

This is the only report of a gastrobronchial fistula in a dog that the authors are aware of. Traumatic reticulo-bronchial fistula in buffalo has been reported.¹ In several reports of gastrobronchial fistulae in humans, the leading causes of acquired gastrobronchial fistulae were trauma ($n = 4$), gastric ulcer ($n = 3$), and subphrenic abscess ($n = 3$).^{2,3} Other reported causes are congenital, previous para-

esophageal or gastroesophageal surgery, infection caused by a foreign body, or neoplasia.² Regardless of etiology, occurrence of gastrobronchial fistula in humans or animals is rare.

The best method of confirming a presumptive diagnosis of gastrobronchial fistula is by an upper gastrointestinal contrast study.⁴ Other diagnostic methods include fiberoptic gastroscopy or bronchoscopy, methylene blue or pH measurement of bronchial secretions, and thoraco-abdominal computed tomography.⁴ A gastrobronchial fistula is considered in human patients with recurrent lower lobar pneumonia and upper abdominal symptoms.² Early treatment by thoracotomy is advised to relieve aspiration.⁵ The gastrobronchial fistula in this dog was chronic and may have been due to foreign body trauma, however, no evidence of a foreign body was found.

REFERENCES

1. Bhardwaj RL, Sharma DN, Krishnamurthy D, Nassimi MN, Peshin PK, Chandna IS. Traumatic reticulo-bronchial fistula in a she-buffalo. *Indian Veterinary Journal* May 1985;62:430-432.
2. Cameron EW, Colby JM, Swanson RS. Gastrobronchial fistula in untreated lymphoma. *Journal of Thoracic Imaging* 1996;11:150-152.
3. Richardson AJ, Tait N, O'Rourke IO. Gastrobronchial fistula owing to non-malignant causes. *British Journal of Surgery*. April 1992;79:331-332.
4. Barcons M, Betbesé A, Pérez M, Vallaverdú I, Net A, Mancebo J. Gastrobronchial fistula: report of an unusual case.
5. Al-Qudah A. Traumatic gastrobronchial fistula: case report and review of the literature. *Journal of Pediatric Surgery* 1997;32:1798-1800.